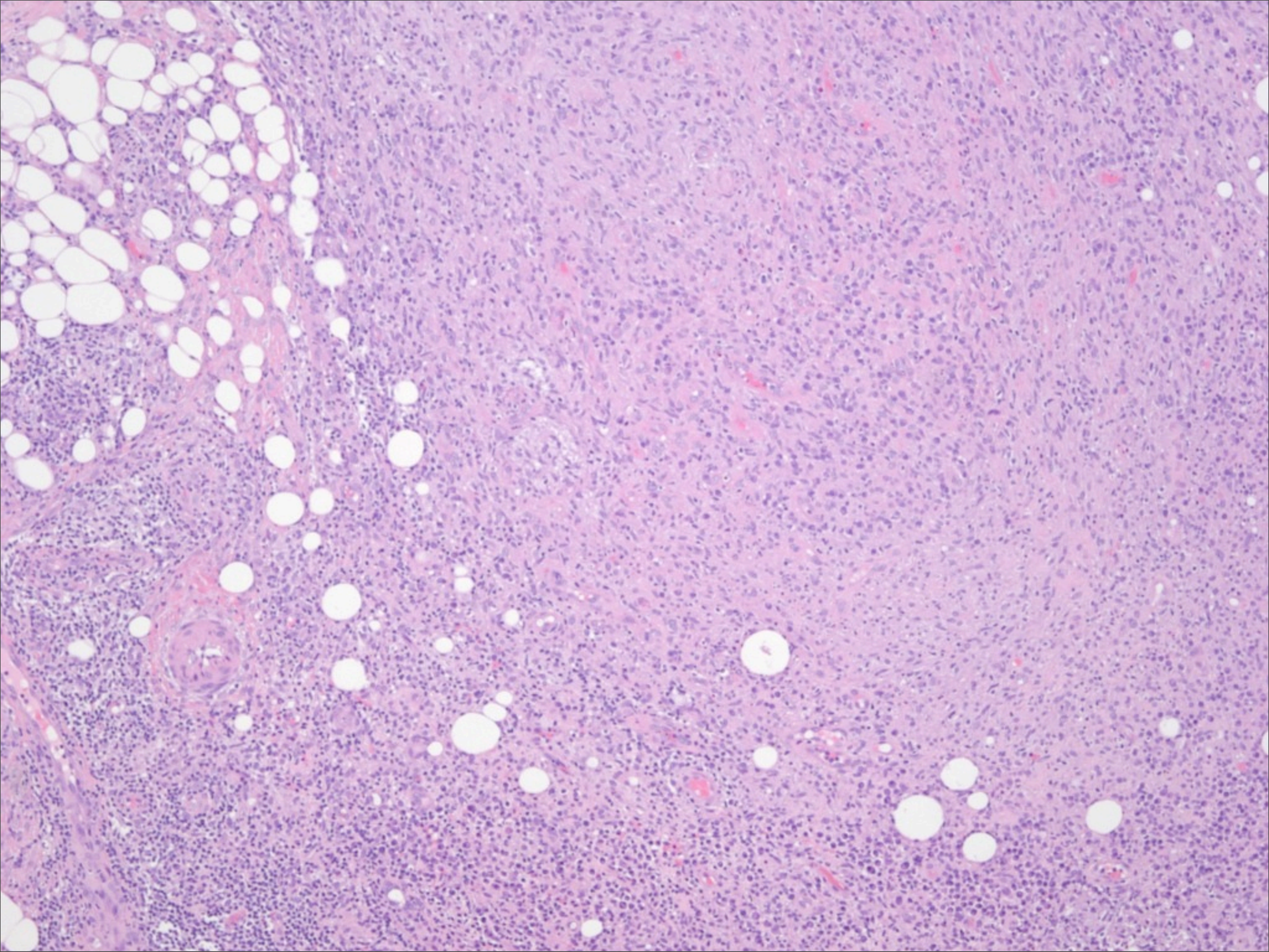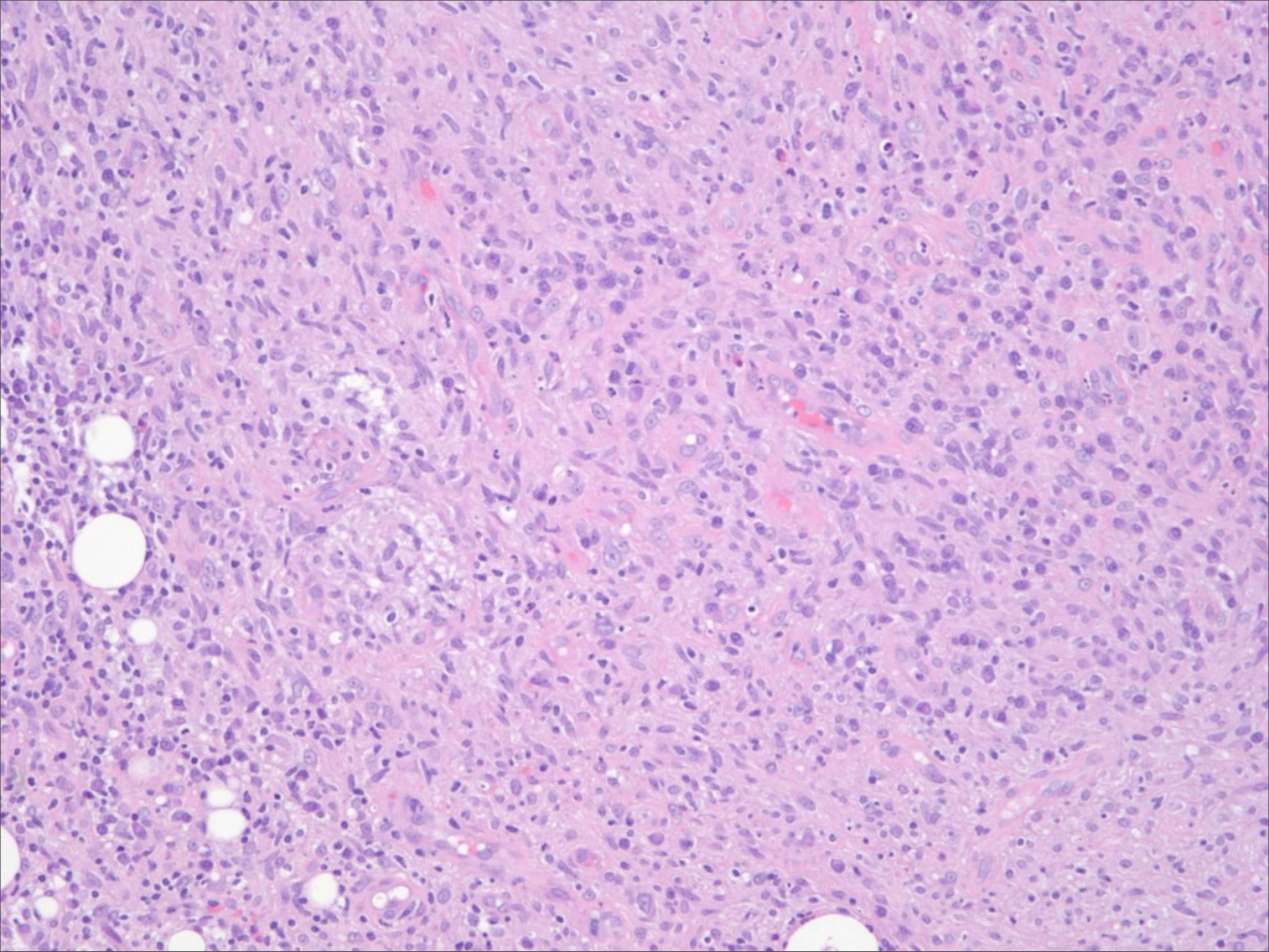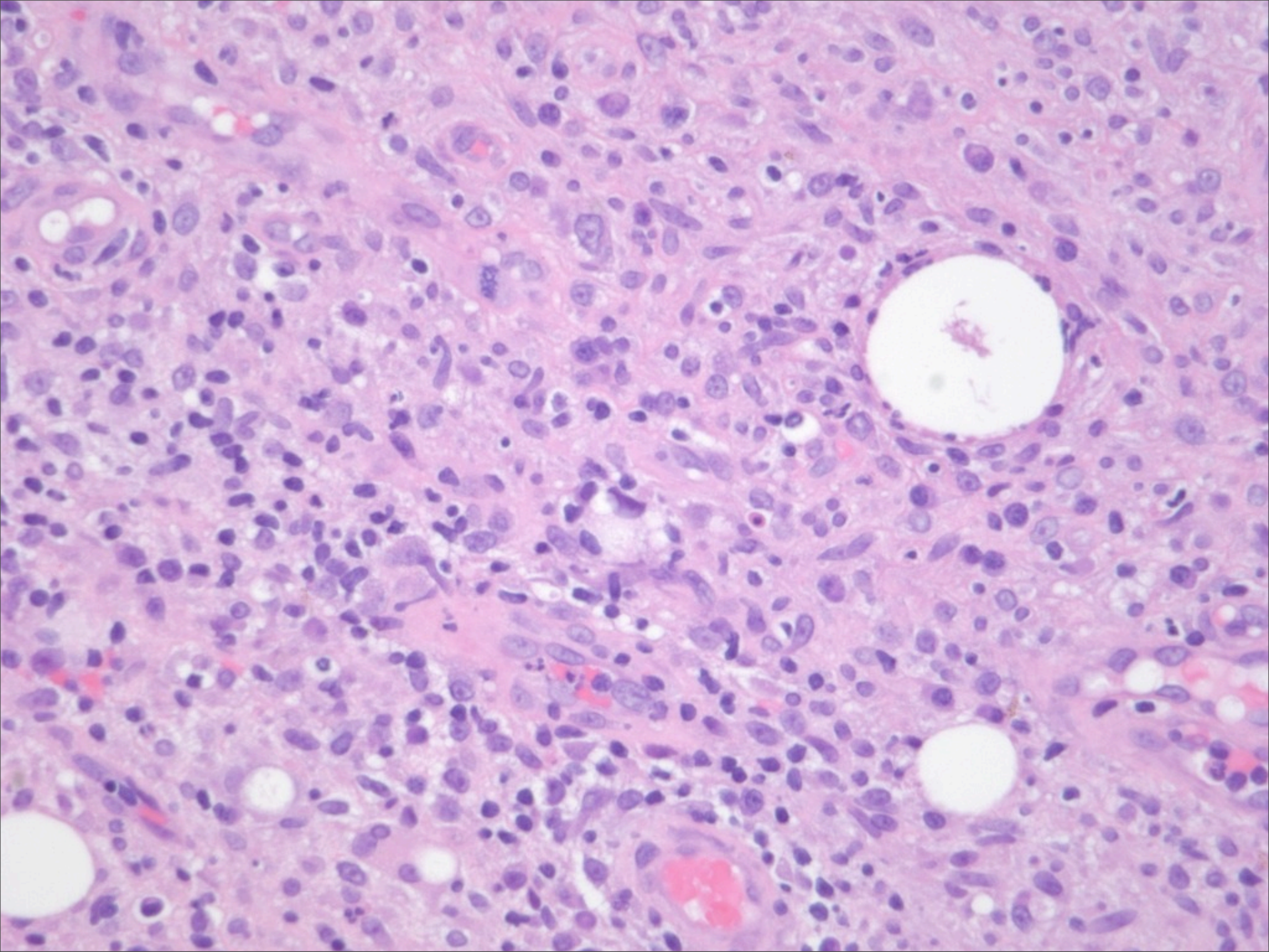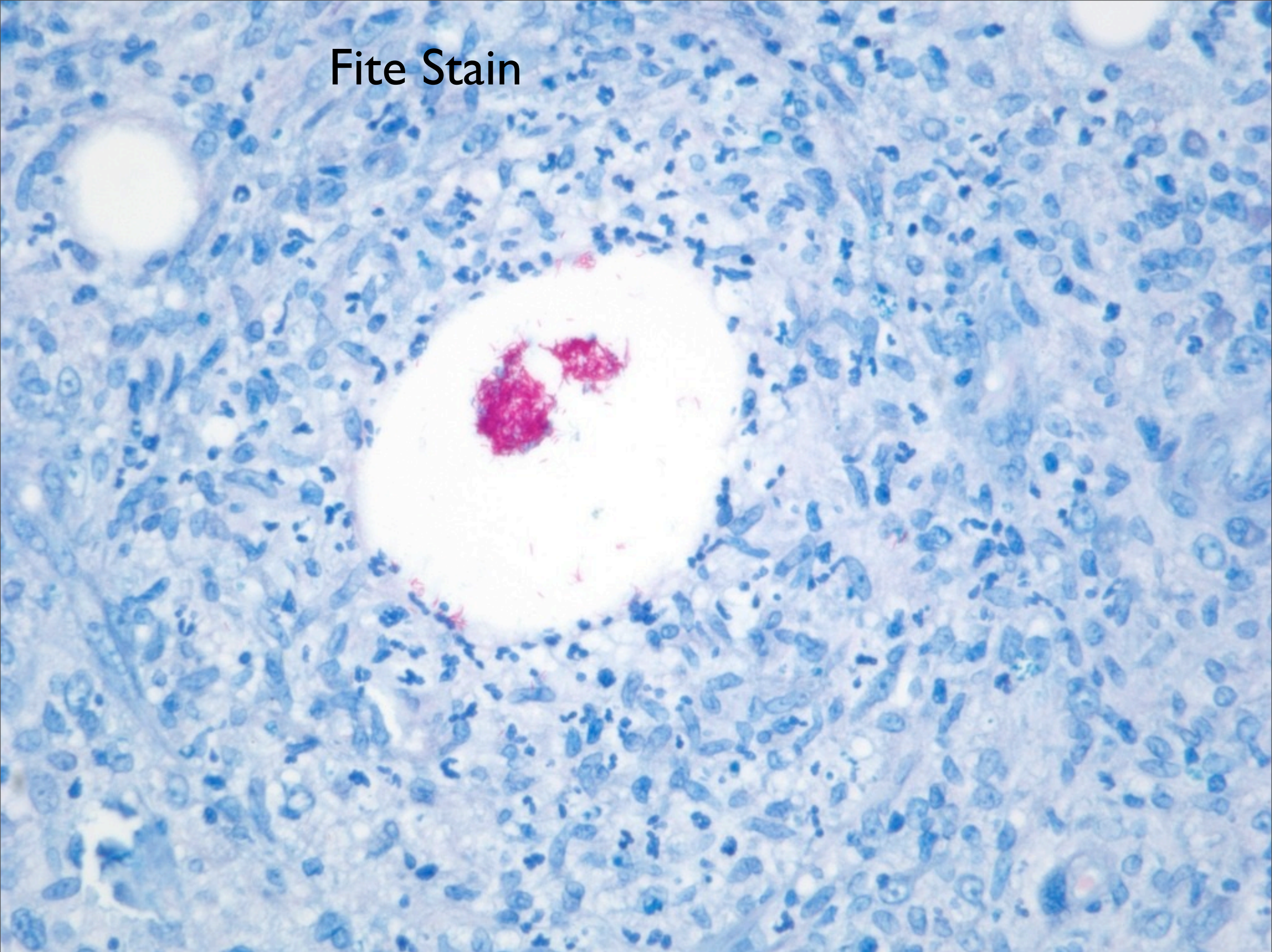
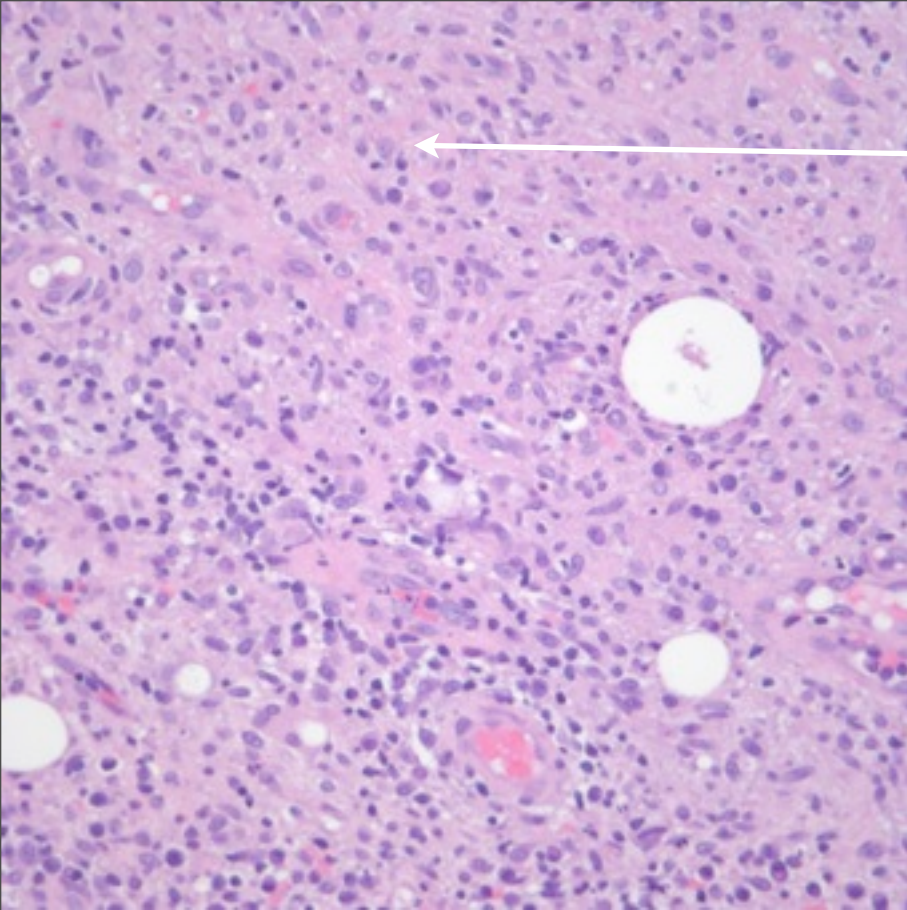


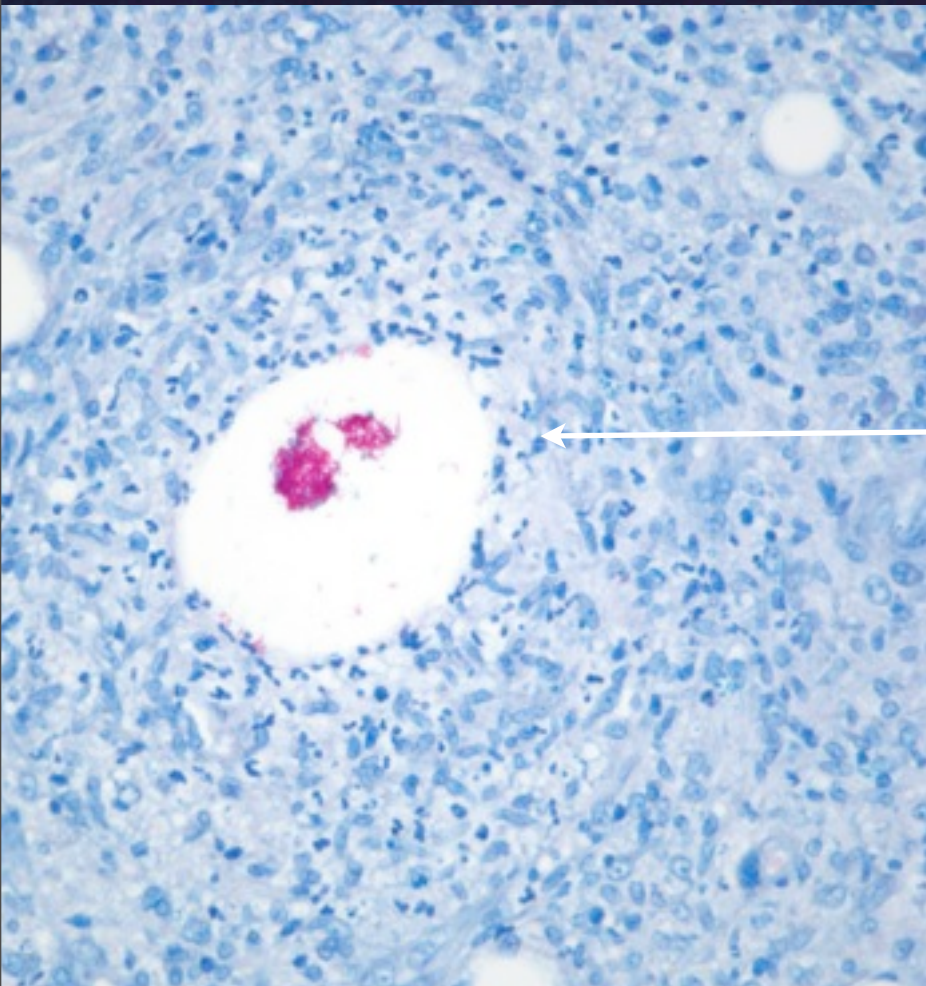
Fite Stain



Atypical Mycobacterium chelonae



Necrobiotic granulomas



Cystic Spaces Filled
with Acid Fast Bacilli